

## Update on porcine circovirus and postweaning multisystemic wasting syndrome (PMWS)

Steven D. Sorden, DVM, PhD, Dipl ACVP

### Summary

Postweaning multisystemic wasting syndrome (PMWS) is a recently emerged disease of nursery and grower pigs associated with type 2 porcine circovirus (PCV2) infection. A proposed case definition of PMWS requires that a pig/group of pigs have all of the following: 1) clinical signs characterized by wasting/failure to thrive, with or without dyspnea or icterus; 2) histologic lesions characterized by depletion of lymphoid tissues and/or lymphohistiocytic to granulomatous inflammation in any organ, typically lungs and/or lymphoid tissues; and 3) PCV2 within characteristic lesions. Immunohistochemistry and in situ hybridization applied to formalin-fixed tissues are the preferred methods for demonstrating PCV2 antigen or genome, respectively, within PMWS lesions. Since available evidence indicates that PCV2 infection is much more common than PMWS, demonstrating PCV2 exposure via serology or infection via isolation or PCR without localizing PCV2 within characteristic lesions cannot constitute a diagnosis of PMWS. To date, consistent experimental reproduction of severe PMWS has only been accomplished via PCV2-parvovirus or PCV2-PRRSV co-infection. Effective control of PMWS will require an understanding of the viral and nonviral cofactors that enable PCV2, an apparently ubiquitous and generally nonpathogenic agent, to induce PMWS.

**Keywords:** swine, postweaning multisystemic wasting syndrome (PMWS), porcine circovirus

**Received:** November 18, 1999

**Accepted:** March 2, 2000

Veterinary Diagnostic Laboratory, Department of Veterinary Diagnostic and Production Animal Medicine, College of Veterinary Medicine, Iowa State University, Ames, Iowa 50011-1250; email: [ssorden@iastate.edu](mailto:ssorden@iastate.edu)

This article is available online at <http://www.aasp.org/shap.html>.

*This diagnostic note has been refereed.*

Sorden SD. Update on porcine circovirus and postweaning multisystemic wasting syndrome (PMWS). *Swine Health Prod.* 2000;8(3):133-136.

Postweaning multisystemic wasting syndrome (PMWS) was first reported in 1995-96 by Harding and Clark.<sup>1,2</sup> In 1997, these authors published a *Diagnostic Note* in *Swine Health and Production* describing the recognition and diagnosis of this syndrome.<sup>3</sup> Since that time, PMWS has been reported in swine-producing countries worldwide, and much has been published about the syndrome and porcine circovirus (PCV).<sup>4-10</sup> The purpose of this paper is to provide both a diagnostic update and a perspective from the midwestern United States (Iowa) on PMWS and PCV.

### Porcine circovirus (PCV)

Porcine circovirus is a very small (17 nm), nonenveloped, single-stranded DNA virus. Type 1 PCV (PCV1) is a contaminant of the PK-15 cell line that was first described over 20 years ago.<sup>11,12</sup> Inoculation of cesarean-derived, colostrum-deprived pigs with PCV1 results in viral replication but fails to induce lesions or disease.<sup>12,13</sup> Type 2 PCV (PCV2) is consistently demonstrated in PMWS lesions and was first identified and characterized in 1998.<sup>4-6,14</sup> The serotype and genotype of PCV2 is markedly different from that of PCV1.<sup>4-6,9,10,14</sup> It is currently uncertain whether the PCV that has been associated with congenital tremors is PCV1 or PCV2.<sup>15</sup>

### PMWS: Definition and diagnosis

Postweaning multisystemic wasting syndrome is a disease of nursery and grower pigs that is characterized clinically by progressive dyspnea and emaciation; diarrhea, pallor, and jaundice are less-consistent

clinical signs.<sup>3,16</sup> Morbidity is typically 5%-15%. Diagnosis of PMWS is based on demonstration of characteristic histologic lesions, and these lesions consistently contain PCV2.<sup>4-6,9,10,14</sup>

Although a formal definition of PMWS has not been explicitly stated, I submit that diagnosis of PMWS requires that a pig/group of pigs exhibit **all** of the following:

- clinical signs: wasting/weight loss/ill thrift/failure to thrive (Figure 1), with or without dyspnea or icterus;
- histologic lesions: depletion of lymphoid organs/tissues and/or lymphohistiocytic to granulomatous inflammation in any organ (typically lungs and/or lymphoid tissues, and less often liver, kidney, pancreas, intestine);
- PCV2 infection within characteristic lesions.

Note the following implications of this definition:

- Clinical signs are not diagnostic. There are many causes of poor performance in nursery and grower pigs.<sup>3</sup>
- Gross lesions are not diagnostic. Although pigs with PMWS typically have interstitial pneumonia, characterized by mottled red and tan, rubbery, noncollapsed lungs, and moderate to severe lymph-node enlargement (Figure 2), these lesions are nonspecific and are also found in other diseases, especially porcine reproductive and respiratory syndrome (PRRS) and septicemic salmonellosis. Furthermore, gross lesions caused by concurrent bacterial and viral infections may modify/obscure PMWS lesions.
- **PCV2 infection ≠ PMWS.** Both lesions and PCV2 must be present to diagnose PMWS in a poorly performing pig.

## Tissues to submit for diagnosis

Since diagnosis of PMWS requires the demonstration of PCV2 in histologic lesions, submission of formalin-fixed tissues to a diagnostic laboratory is required; if PMWS diagnosis is the only objective, then only formalin-fixed tissues need be submitted. The preferred specimens are small portions of lung (three to four samples), lymphoid tissues (tonsil, thymus, spleen, ileum [Peyer's patch], enlarged lymph nodes), liver, kidney, and pancreas. Stomach, duodenum, jejunum, and colon are also sometimes useful. If PCV2 isolation is desired, and/or to rule out other infectious agents, chilled samples of fresh lung, tonsil, thymus, spleen, ileum, enlarged lymph nodes, liver, and kidney should also be submitted.

## Detecting PCV2 infection

Clusters of globular intracytoplasmic inclusion bodies are frequently present in macrophages within PMWS lesions; these inclusions are consistent with those found in circoviral diseases in other species and were the first indication of a potential viral cause of PMWS.<sup>1,3</sup> When such inclusions are present and typical, they are reliable indicators of PCV2 infection; however, in our experience inclusions are present in less than half of PMWS cases, and when present may vary considerably in morphology. For these reasons, other methods are usually required to detect PCV2 infection.

## Immunohistochemistry and in situ hybridization

Multiple methods have been developed to detect PCV2 infection.<sup>4-6,14,17-19</sup> The sensitivity and specificity of most of these methods have not been rigorously established or compared. Because diagnosing PMWS requires demonstration of PCV2 within histologic lesions (Figure 3), immunohistochemistry (IHC) for PCV2 antigen or in situ hybridization (ISH) for PCV2 nucleic acid are the preferred diagnostic methods. Both of these tests are performed on paraffin-embedded, formalin-fixed tissues. Both polyclonal antisera and monoclonal antibodies have been used for PCV2 IHC,<sup>4,7,17,20</sup> and several groups have developed ISH probes that detect PCV2 nucleic acid.<sup>5,6,17,18</sup> In general, IHC is more rapid and economical than ISH; a recent report indicates that ISH may detect more positive cells.<sup>17</sup>

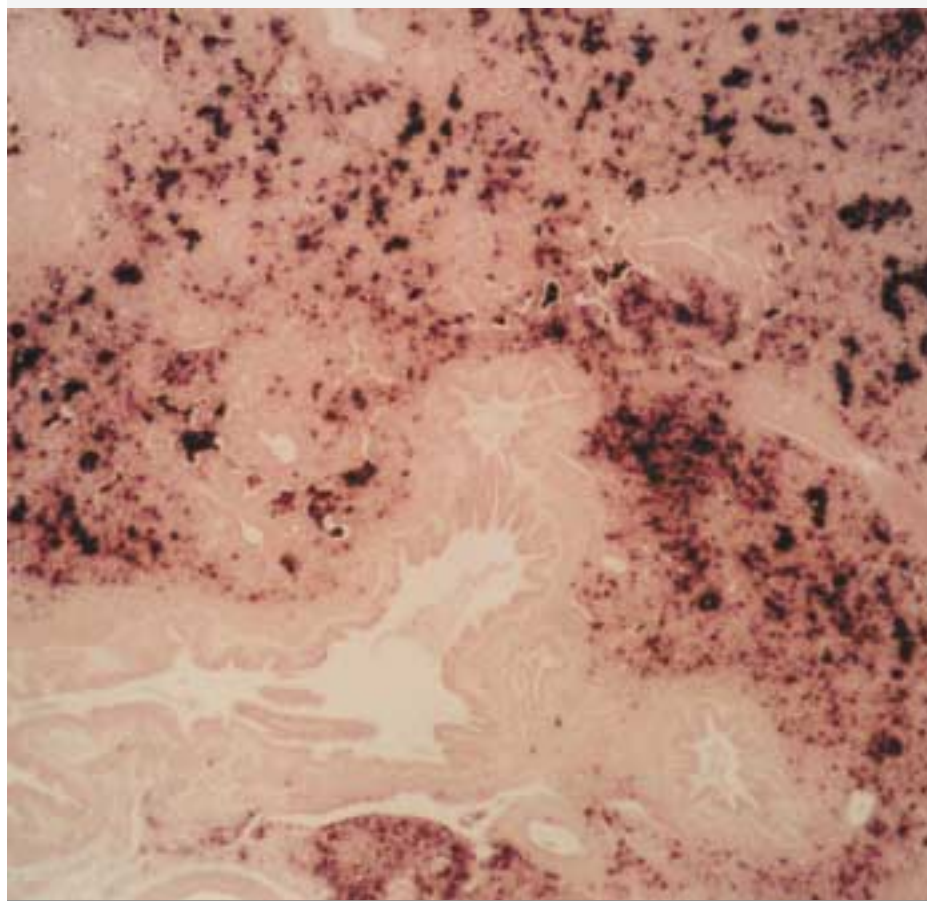
**Figure 1.** PMWS was diagnosed at necropsy in the emaciated, long-haired pig in the foreground; this pig entered the finisher at approximately the same weight as the unaffected pig in the background.



**Figure 2.** Lungs from a pig with PMWS are diffusely noncollapsed, mottled red and tan, and have a rubbery texture. The esophagus is displaced laterally by the severely enlarged lymph nodes. These gross lesions are indistinguishable from PRRS or salmonellosis.



**Figure 3.** In situ hybridization demonstrates abundant PCV2 genome (black reaction product) in this histologic section of lung with severe interstitial pneumonia from a pig with PMWS. Relative sparing of the airways (lower half of photomicrograph) is typical.



### Virus isolation

PCV2 infection has also been demonstrated via virus isolation (VI)<sup>4,6,9,10</sup> or polymerase chain reaction (PCR).<sup>6,14,19,21</sup> Isolation of PCV2 is performed in PK-15 cells that are free of PCV1 contamination. Virus isolation is time consuming and does not appear to be as sensitive as IHC or ISH. However, PCV2 isolates are currently desirable for research purposes and may someday be of clinical value for typing (via nucleotide sequencing or monoclonal antibody analysis) or possibly for the production of autogenous vaccines.

### Polymerase chain reaction

Polymerase chain reaction (PCR) assays that can differentiate PCV1 and PCV2 have been developed,<sup>19</sup> and PCR can thus be used to type viral isolates; to date, all PCV isolates in our laboratory have been type 2 (unpublished observation). Although PCR may be used for the direct detection of PCV2 in tissues, it is important to recognize that PCV2 infection can

occur in the absence of PMWS;<sup>21</sup> we have observed PCV2 infection in tonsils from healthy pigs obtained at slaughter (unpublished observation). Furthermore, since circoviral particles are highly resistant and likely to persist in the environment for extended periods of time,<sup>22</sup> the potential for PCV2 contamination of tissues obtained in the field or the laboratory is high. Given the apparent ubiquity and environmental stability of PCV2, it is my opinion that PCR may be too sensitive to be useful for the routine diagnosis of PMWS.

### PCV2 serology

Indirect immunofluorescence assays (IIFA) have been developed for both PCV1 and PCV2. Several reports indicate a high prevalence of antibodies to PCV1.<sup>23–25</sup> PCV2 seroprevalence is also reported to be very high,<sup>5,26</sup> and this is consistent with our observations; we have been unable to identify a seronegative swine herd. We recently tested sow serum from 28 high-health herds; most sows in all of these

herds were seropositive, but none reported experiencing PMWS (Sorden SD, Halbur PG, Harms PA, *unpublished data*). Serology is of little use in PMWS diagnosis but might be of value in determining when in the late nursery or early finishing phase seroconversion occurs in a given herd.

### Diagnostic trends

At the Iowa State University Veterinary Diagnostic Laboratory, PMWS/PCV2 infection was diagnosed in

- 16 herds in 1997,
- 111 herds in 1998, and
- 449 herds in 1999.

Most cases are in the late nursery/early grow-finish age groups, and morbidity typically ranges from 5%–15%. Most cases have interstitial pneumonia, and lung and lymphoid tissues are the most common sites in which PCV2 infection is demonstrated (primarily by IHC). Porcine reproductive and respiratory syndrome virus (PRRSV) is the most common co-infecting agent, and is demonstrated (predominantly by IHC) in over 60% of cases of PMWS; given the relative insensitivity of IHC for diagnosing PRRSV infection, we suspect that the true incidence of PRRSV and PCV2 co-infection is higher. This is in contrast to the situation in western Canada, in which only approximately 20% of PMWS cases have evidence of concurrent PRRSV infection.<sup>27</sup>

Clark and Harding first identified PMWS in a western Canadian herd in 1991.<sup>1,2</sup> We recently performed a retrospective study in which in situ hybridization for PCV2 was applied to archived paraffin tissue blocks dating from 1993.<sup>28</sup> Tissues exhibiting lesions consistent with PMWS and containing abundant PCV2 genome were identified in cases submitted as early as September 1993. Severe depletion of lymphoid tissues was associated with high numbers of PCV2-containing cells within those tissues. Lung lesions typically associated with high numbers of PCV2-containing cells included severe lymphohistiocytic to granulomatous interstitial pneumonia, and airway epithelial attenuation or erosion, as well as partial obliteration of airway lumens by fibrous connective tissue. Low numbers of PCV2-containing cells were typically found within lymphoid follicles in tissues such as Peyer's patch, tonsil, lymph node, or spleen that were

histologically unremarkable.

## Does PCV2 cause PMWS?

Lymphoid depletion and hepatic disease consistent with PMWS have been reproduced in gnotobiotic or colostrum-deprived pigs with inocula containing PCV2 and porcine parvovirus.<sup>7,8</sup> To date, consistent reproduction of severe PMWS in the absence of parvovirus co-infection has not been reported.<sup>29</sup> We have reproduced severe interstitial pneumonia and other features of PMWS by co-infecting cesarean-derived/colostrum-deprived pigs with PCV2 and PRRSV.<sup>30</sup> Although it is clear that PCV2 infection is necessary for the development of PMWS, it appears that other factors, such as co-infecting viruses, are also required.

As noted above, sporadic cases of PMWS occurred as early as 1991 in western Canada and 1993 in the United States.

Why PMWS has emerged as a significant problem within the last 4–5 years is uncertain. All available evidence indicates that PCV2 infection is extremely common,<sup>5,16,21,26</sup> yet only a minority of infected herds (and pigs) develop PMWS. Whether different PCV2 isolates vary in virulence has not been determined. Additional research will be required to explain the emergence of this new syndrome and to identify the cofactors that enable PCV2, an apparently ubiquitous and usually non-pathogenic agent, to induce PMWS.

## References

- Ellis J, Hazzard L, Clark E, Harding J, Allan G, et al. Isolation of circovirus from lesions of pigs with post-weaning multisystemic wasting syndrome. *Can Vet J* 1998; 39:44–51.
- Allan GM, McNeilly F, Kennedy S, Daft B, Clark EG, Ellis JA, Haines DM, Meehan BM, Adair BM. Isolation of porcine circovirus-like viruses from pigs with a wasting disease in the USA and Europe. *J Vet Diagn Invest* 1998; 10:3–10.
- Morozov I, Sirinarumitr T, Sorden SD, Halbur PG, Morgan MK, Yoon K-J, Paul PS. Detection of a novel strain of porcine circovirus in pigs with postweaning multisystemic wasting syndrome (PMWS). *J Clin Microbiol* 1998; 36:2535–2541.
- Ellis J, Krakowka S, Lairmore M, et al. Reproduction of lesions of postweaning multisystemic wasting syndrome in gnotobiotic piglets. *J Vet Diagn Invest* 1999; 11:3–14.
- Allan GM, Kennedy S, McNeilly F, et al. Experimental reproduction of severe wasting disease by co-infection of pigs with porcine circovirus and porcine parvovirus. *J Comp Pathol* 1999; 121:1–11.
- Meehan BM, McNeilly F, Todd D, Kennedy S, et al. Characterization of novel circovirus DNAs associated with wasting syndromes in pigs. *J Gen Virol* 1998; 79:2171–2179.
- Allan GM, Mc Neilly F, Meehan BM, et al. Isolation and characterisation of circoviruses from pigs with wasting syndromes in Spain, Denmark and Northern Ireland. *Vet Microbiol* 1999; 66:115–123.
- Tischer I, Gelderblom H, Vetterman W, Koch MA. A very small porcine virus with circular single-stranded DNA. *Nature* 1982; 295:64–66.
- Tischer I, Miels W, Wolff D, Vagt M, Griem W. Studies on epidemiology and pathogenicity of porcine circovirus. *Arch Virol* 1986;91:271–276.
- Allan GM, McNeilly F, Cassidy JP, Reilly GAC, Adair B. Pathogenesis of porcine circovirus, experimental infections of colostrum deprived piglets and examination of pig fetal material. *Vet Microbiol* 1995; 44, 49–64.
- Hamel AL, Lihua LL, Nayar GPS. Nucleotide sequences of porcine circovirus associated with postweaning multisystemic wasting syndrome in pigs. *J Virol* 1998; 72:5262–5267.
- Harding JCS, Clark EG, Strokappe JH, Willson PI, Ellis JA. Postweaning multisystemic wasting syndrome: Epidemiology and clinical presentation. *Swine Health Prod* 1998; 6:249–254
- McNeilly F, Kennedy S, Moffett D, et al. A comparison of in situ hybridization and immunohistochemistry for the detection of a new porcine circovirus in formalin-fixed tissues from pigs with post-weaning multisystemic wasting syndrome (PMWS). *J Virol Methods* 1999; 80:123–128.
- Choi C, Chae C. In-situ hybridization for the detection of porcine circovirus in pigs with postweaning multisystemic wasting syndrome. *J Comp Pathol* 1999; 121:265–270.
- Larochelle R, Antaya M, Morin M, Magar R. Typing of porcine circovirus in clinical specimens by multiplex PCR. *J Virol Methods* 1999; 80:69–75.
- Sorden SD, Harms PA, Nawagitgul P, Cavanaugh D, Paul PS. Development of a polyclonal-antibody-based immunohistochemical method for the detection of type 2 porcine circovirus in formalin-fixed, paraffin-embedded tissue. *J Vet Diagn Invest* 1999; 11:528–530.
- Larochelle R, Morin M, Antaya M, Magar R. Identification and incidence of porcine circovirus in routine field cases in Quebec as determined by PCR. *Vet Rec* 1999; 145:140–142.
- Allan JM, Phenix KV, Todd D, McNulty MS. Some biological and physico-chemical properties of porcine circovirus. *J Vet Med B* 1994; 41:17–26.
- Tischer I, Miels W, Wolff D, Vagt M, Greim W. Studies on epidemiology and pathogenicity of porcine circovirus. *Arch Virol* 1986; 91:271–276.
- Dulac GC, Afshar A. Porcine circovirus antigens in PK-15 cell line (ATCC CCL-33) and evidence of antibodies to circovirus in Canadian pigs. *Can J Vet Res* 1989;53:431–433.
- Hines RK, Lukert PD. Porcine circovirus: A serological survey of swine in the United States. *Swine Health Prod* 1995; 3:71–73.
- Allan GM, Ellis JA. Porcine circoviruses: a review. *J Vet Diagn Invest* 2000; 12:3–14.
- Balasz M, Segales J, Rosell C, et al. Experimental inoculation of conventional pigs with tissue homogenates from pigs with post-weaning multisystemic wasting syndrome. *J Comp Pathol* 1999; 121:139–148.

## References - nonrefereed

- Clark EG. Post-weaning multisystemic wasting syndrome. *Proc AASP Ann Meet* 1997:499–501.
- Harding JC. Post-weaning multisystemic wasting syndrome (PMWS): Preliminary epidemiology and clinical presentation. *Proc AASP Ann Meet* 1997; 503.
- Harding JCS, Clark EG. Recognizing and diagnosing postweaning multisystemic wasting syndrome (PMWS). *Swine Health Prod* 1997; 5:201–203.
- Hines RK, Lukert PD. Porcine circovirus as a cause of congenital tremors in newborn pigs. *Proc AASP Ann Meet* 1994; 344–345.
- Harding JCS, Clark EG, Ellis JA. The clinical expression of porcine circovirus. *Proceedings, Allen D. Leman Swine Conference*, 1999; 252–254.
- Sorden SD, Thacker, BJ, Harms PA, Sirinarumitr T, Morozov I, Paul PS. Retrospective study of porcine circovirus infection in porcine tissues submitted to the Iowa State University Veterinary Diagnostic Laboratory using in situ hybridization. *Proc AAVLD Ann Meet* (abstract), October 1999.
- Harms PA, Sorden SD, Halbur PG. Experimental reproduction of severe disease in CD/CD pigs co-infected with PRRSV and type 2 porcine circovirus. *Proc AASP Ann Meet* 2000; 325–326.

